

Series Editors: Angelo P. Giardino, MD, PhD
Patrick S. Pasquariello, Jr., MD

An 18-Month-Old Boy with Progressive Hoarseness

Russell A. Faust, PhD, MD

CASE PRESENTATION

History

An 18-month-old boy was brought by his mother to an outpatient clinic with the complaint of a “raspy voice” that had worsened over the previous 8 to 12 weeks. The child recently experienced periods when he lost his voice, which prompted the mother to seek medical attention.

When asked about the child’s voice changes, the mother indicated that her son’s voice did not become weaker (fatigue) throughout the day. The mother denied any choking, difficulty swallowing, cough, episodes of respiratory distress, cyanosis, acute life-threatening events, or trauma. However, she admitted to witnessing brief episodes of stridor during the 2 to 3 weeks prior to the clinic visit. Further inquiry suggested that the child had been experiencing transient periods of increased work of breathing with retractions.

The child’s birth history was unremarkable, with full-term gestation and spontaneous vaginal delivery to a G1,P1 mother, age 19 years. The child’s medical history was negative for neonatal intensive care stay, intubation, or surgery. He was taking no medications and had no known drug allergies. The mother reported that the child was a “spitty” baby until approximately age 11 or 12 months; he was never treated for gastroesophageal reflux disease (GERD).

Physical Examination

A rapid assessment of the child revealed all vital signs within normal range for age and no evidence of respiratory distress. The toddler was in no apparent distress, was not cyanotic, and did not appear ill or dyspneic. He was breathing comfortably, without audible stridor or wheeze. Auscultation of the neck revealed faint stridor. The child’s voice was raspy. He had normal hearing. The remainder of the otolaryngologic examination was normal, without lesions.

Key Point

Hoarseness (dysphonia) is common in children and often results in pediatrician visits. Although the cause usually is benign or self-limited, certain (even benign) causes of dysphonia in a child may result in imminent airway obstruction or may indicate significant underlying disease and, thus, require prompt diagnosis and management.

- What is the recommended clinical approach to hoarseness in a child?
- What is the differential diagnosis?

CLINICAL APPROACH

The diagnosis and management of dysphonia in the pediatric patient can be challenging, as clinical approaches that are successful in adults often are not helpful or feasible in children. For example, although adults and children with hoarseness can exhibit similar voice qualities, the pathologic etiologies can differ significantly. Also, the standard methods for evaluating voice disorders in adults—indirect laryngoscopy using a mirror, flexible fiberoptic nasolaryngoscopy, and stroboscopic video laryngoscopy—may not be successful, depending on the child’s age and level of cooperation. Furthermore, once a diagnosis is made, children are often noncompliant with voice hygiene and voice therapy regimens, and

(continued on page 41)

Dr. Faust is the Carls Foundation Endowed Chair of Otolaryngology and the Director of the Carls Communications Disorders Program, Children’s Hospital of Michigan; he also is a member of the faculty of the Karmanos Cancer Institute, Detroit, MI. Dr. Giardino is the Vice President for Clinical Affairs and the Associate Chair of Pediatrics, St. Christopher’s Hospital for Children, Philadelphia, PA; he also is a member of the Hospital Physician Editorial Board. Dr. Pasquariello is the Director of the Diagnostic Center, Division of General Pediatrics, Department of Pediatrics, Children’s Hospital of Philadelphia, Philadelphia, PA.

(from page 38)

surgical procedures that are successful in adults may be impractical in children (eg, due to lack of postoperative compliance with voice rest).

Fortunately, the vast majority of children with dysphonia have benign disorders that are easy to evaluate and manage. This care usually is best approached as a team effort, starting with a pediatrician or primary care physician and extending to include a pediatric otolaryngologist, a speech-language pathologist, and other specialists, if results of initial evaluation warrant.

Approach to the History

In gathering the history for a child with hoarseness it is important to always ask about the delivery, any prior intubation or surgery, and other medical conditions. Details surrounding previous intubation should include the circumstances, endotracheal tube size, duration of intubation, and whether multiple intubations occurred. Some medical conditions may exacerbate voice disorders. Certain medications (eg, some drying antihistamines or inhalers) may cause laryngeal irritation or dryness or may increase the risk of reflux, and therefore laryngitis. Due to the anatomy of the recurrent laryngeal nerve, some surgical procedures (eg, any surgery of the central nervous system, neck, mediastinum, or heart) may be associated with an increased risk of laryngeal paresis or paralysis and subsequent dysphonia.

The onset of hoarseness can provide a guide to etiology. For example, hoarseness presenting at birth is likely due to a congenital anomaly or neurologic defect; hoarseness that is worse in the morning can indicate laryngitis caused by gastroesophageal reflux. Associated symptoms or medical conditions also may suggest the etiology. Chronic or recurrent cough or throat clearing from any cause (eg, asthma or cystic fibrosis with cough; adenoiditis or sinusitis with postnasal drainage and throat clearing) may result in vocal nodules from repeated impact of the vocal cords. Note that children with hearing loss—or with parents who have hearing loss—are at increased risk for vocal abuse and hoarseness. Also at risk are children exposed to tobacco smoke.

Approach to the Physical Examination

Most important is a rapid assessment of acuity—any hoarse child who is in respiratory distress should be evaluated at a facility with respiratory and operative support available. The physical examination should include a thorough head and neck examination, including cranial nerve assessment and examination of the neck for masses; auscultation of the neck and chest for stertor, stridor,

or wheezing; and evaluation of the upper respiratory mucosa for evidence of infection, vascular lesions (hemangiomas, lymphatic malformations), or masses (papillomas). A comprehensive hearing examination is necessary in all children with dysphonia.

Evaluation by a Speech-Language Pathologist

To optimize evaluation of the child with hoarseness, an examination by a speech-language pathologist ideally should be performed in collaboration with the otolaryngologist's assessment. Visualization of the larynx is necessary for diagnosis and may be accomplished by flexible nasolaryngoscopy in the clinic or by operative endoscopy under general anesthesia. Stroboscopic video laryngoscopy helps illustrate vocal cord vibration in apparent slow motion, thus revealing subtle lesions that may not be appreciated otherwise. This clinical examination requires an awake and cooperative patient and therefore is often impossible in infants and young children. Finally, some authorities advocate pH monitoring to aid in the diagnosis of GERD as a possible contributor to hoarseness,¹ although this is especially controversial in children.^{2,3} Others advocate esophagoscopy with biopsies to look for evidence of reflux esophagitis.²

DIFFERENTIAL DIAGNOSIS

The differential diagnosis of dysphonia in children is extensive.⁴ Despite the potential for hoarseness to reflect a catastrophic underlying pathology, the causes are much more likely to be benign than the causes of dysphonia in an adult.

Acute Hoarseness (\leq 2 Weeks' Duration)

In a child with acute hoarseness, the most common causes are inflammatory and include viral laryngitis, viral laryngotracheitis, adenoiditis with postnasal drip and throat clearing, and sinonasal infections with postnasal drip and throat clearing. Many of these conditions do not persist longer than 2 weeks and are self-limited. The most common acute cause of dysphonia is a viral upper respiratory illness; given the typically self-limited nature of such infections, a posture of expectant observation is most appropriate.

Chronic Hoarseness

In a child with long-standing hoarseness, vocal nodules are the leading cause. Chronic or persistent cough may result in so-called *screamer's nodules* from repeated impact of vocal folds against one another. Once vocal nodules are established, other common medical conditions may also contribute to laryngitis and the persistence

or exacerbation of vocal nodules. These include any condition that causes a chronic or recurrent cough (asthma, cystic fibrosis) or throat-clearing behavior (adenoiditis or allergic rhinitis with postnasal drainage). Treatment of these underlying disorders can improve the voice. Vocal nodules also are exacerbated by GERD, and a trial of antireflux therapy will often improve the voice in a child with vocal nodules. The management of vocal nodules in children is somewhat controversial, but many authorities advocate a conservative posture of voice therapy, antireflux therapy, improved management of asthma or other disorders, and avoidance of surgical intervention.⁵ In one study, voice therapy resulted in voice improvement in 86% of children with vocal nodules.⁵

Key Point

Although a nuisance and a therapeutic challenge in children, vocal nodules do not progress to compromise the airway, are self-limited, and often resolve with voice therapy.

Long-term hoarseness also may be the result of chronic inflammation of the larynx due to various underlying conditions. In such cases, the hoarseness may persist for long periods and often exhibits a waxing-and-waning course that follows the natural history of the primary disorder. In a child with hoarseness associated with chronic cough (eg, due to asthma or GERD) an attempt should be made to manage the underlying cause more aggressively. In the clinical context of obvious GERD, there is a ready explanation for dysphonia. However, most children with reflux do not exhibit outward signs or complaints, making the diagnosis of GERD especially challenging. Indeed, in many children, reflux manifests as airway symptoms such as bronchospasm, laryngospasm, cough, and dysphonia.^{2,6} When other causes have been excluded, a trial of an H₂-receptor blocker or proton pump inhibitor may have diagnostic as well as therapeutic value. Even if the child has asthma and there is no strong history of reflux, an empiric trial of antireflux therapy will often improve voice quality significantly. In the author's practice, GERD is presumed to play some role in the pathophysiology of dysphonia in all children we evaluate, and antireflux therapy is included in our therapeutic regimen for dysphonia.⁴

Progressive Hoarseness of Recent Onset (> 2 Weeks)

A recent onset of a progressive voice change that persists for longer than 2 weeks warrants medical attention with much greater urgency than long-standing

childhood hoarseness, as the differential diagnosis is more concerning.⁴ A voice that becomes breathy as it fatigues during the day or voice changes that are associated with difficulty swallowing or with aspiration point toward a neuromuscular disorder or serious anatomic anomaly, such as a fistula or neoplasm. The most common laryngeal mass or neoplasm in a child is recurrent respiratory papillomatosis (RRP). Any of these diagnoses may present as dysphonia but progress to periods of aphonia or stridor or to respiratory distress. In those children with progressive hoarseness of recent onset who experience aphonia, stridor, or respiratory distress, a neurodegenerative or neoplastic process should be excluded. We should heed Cohen's caution that "voice change may be the earliest clinical sign or symptom of a catastrophic neurological disorder."⁷

Hoarseness in the Neonate or Infant

Dysphonia in the neonate or infant who has required intubation for any reason is most commonly the result of local inflammation and edema at the level of the vocal cords; the hoarseness most often is self-limited and should resolve over days. If it does not, direct inspection is warranted. If there is no history of intubation, the cause may be a congenital anomaly or neuromuscular disorder—most commonly vocal cord paresis or paralysis. The infant's cry may provide clues as to etiology; dysphonia or absent, weak, or breathy cry can indicate vocal cord paralysis, glottic web or cyst, or neurologic dysfunction. Neonates with bilateral vocal cord paralysis usually present with stridor and respiratory distress, whereas unilateral or partial vocal paralysis may merely manifest as a weak or breathy voice or cry.

Key Point

Hoarseness that persists for longer than 2 weeks, is progressive, or is associated with periods of aphonia or stridor should be promptly evaluated. If the hoarseness is associated with respiratory distress, the evaluation should occur in the acute care setting, with resuscitative respiratory support and skilled operative airway intervention (including anesthesiologists) readily available.

CLINICAL COURSE OF CASE PATIENT

The child's history of relentless progression of hoarseness over weeks was cause for alarm and, combined with the absence of previous intubation or surgery, pointed toward a neoplastic cause. The patient was examined in the clinic using flexible fiberoptic nasolaryngoscopy. This examination revealed an exophytic mass consistent with RRP. The patient was subsequently scheduled for general

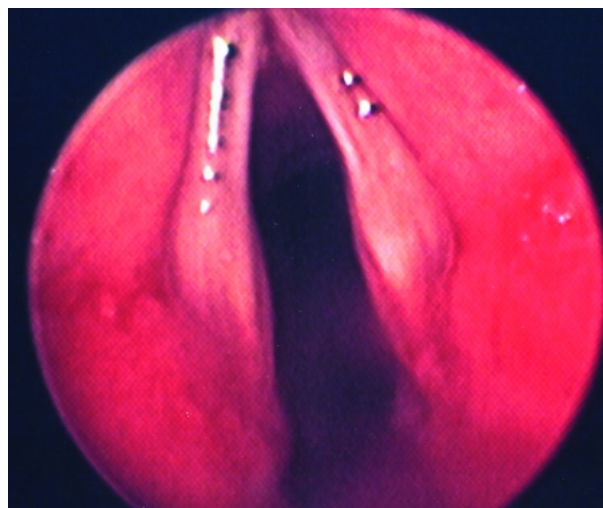
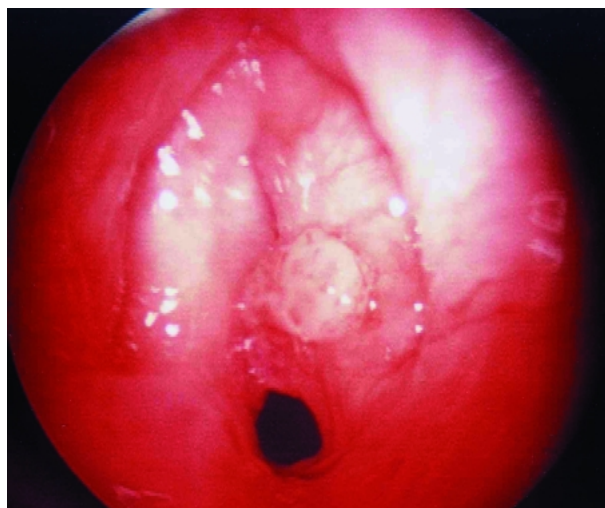


Figure 1. Findings on laryngoscopy of the case patient (A) versus an 18-month-old child with a normal larynx (B). Note the exophytic lesions consistent with recurrent respiratory papillomatosis of the larynx and airway compromise in the case patient and the smooth true vocal cords in the unaffected child.

anesthesia and operative direct laryngoscopy and bronchoscopy with microscopic CO₂ laser excision of the lesions 1 week following the clinic visit.

In the intervening days, the child's hoarseness worsened and he became aphonic and developed mild respiratory distress. He was taken to the operating room 4 days following the initial clinic visit. Laryngoscopy revealed exophytic papilloma lesions (**Figure 1**), which were removed via CO₂ laser under microscopic laryngoscopy. Laryngoscopy 3 weeks subsequent to laser treatment revealed airway improvement but residual disease in the right vocal cord (**Figure 2**). The patient subsequently required similar surgical treatments 3 to 4 times per year.

RECURRENT RESPIRATORY PAPILLOMATOSIS

Etiology

RRP is caused by human papillomavirus (HPV), most commonly types 6 and 11—the same viral subtypes typically associated with genital warts (condyloma acuminata).^{8,9} Transmission to the infant airway usually occurs during birth; therefore, the presence of genital warts in the mother can help guide the diagnosis when evaluating the infant or child with progressive hoarseness. It is likely that the host immune system plays a role in the development of RRP. A role for cytokines has been proposed based on preliminary analysis.¹⁰

Epidemiology

RRP affects individuals of all ages, with the youngest patient identified at 1 day of age and the oldest at

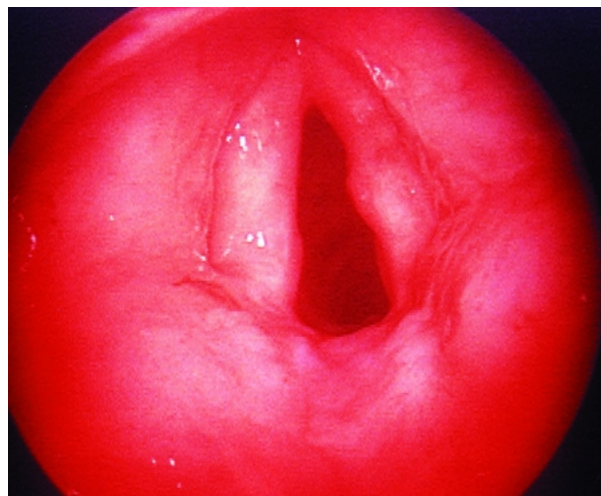


Figure 2. Findings on laryngoscopy of the case patient 3 weeks following CO₂ laser ablation for recurrent respiratory papillomatosis of the larynx. Note the improved airway but residual disease in the right vocal cord.

84 years.¹¹ Among children, RRP is the most common benign neoplasm of the larynx and the second most frequent cause of hoarseness.¹² There are no apparent gender or racial differences in the incidence of RRP and in growth characteristics of RRP lesions in children. In most pediatric series, RRP is diagnosed between 2 and 4 years of age, with a delay from the time of onset of symptoms to diagnosis averaging about 1 year. Patients with childhood-onset RRP are

more likely to be first born to mothers younger than 20 years of age and vaginally delivered than are control patients of similar age.¹³ Kashima and colleagues¹³ speculated that primigravid mothers are more likely to have a prolonged second stage of labor and that the longer exposure to the virus results in a higher risk of infection in the first-born child. They also hypothesized that newly acquired genital HPV lesions are more likely to shed virus than long-standing lesions, further increasing the risk of exposure in younger mothers.

Clinical Manifestations

RRP is characterized by the proliferation of benign squamous papillomas within the aerodigestive tract. Because the most common site for RRP lesions is the vocal fold, infants and children with RRP will present with hoarseness as the most common symptom. The child's voice may be described as weak or breathy from birth. This may progress to aphonia. Stridor often is the second symptom, beginning as inspiratory but progressing to biphasic as the lesions occupy more of the laryngeal airway. Although unusual, RRP may present as chronic cough, dysphagia, or dyspnea. The disease has a variable course but most often is characterized by recurrent growth of lesions after surgical removal. Some patients experience spontaneous remission, whereas others may suffer from aggressive papillomatous growth requiring frequent surgical treatments over many years. According to a national registry of children with RRP (comprised of the clinical practices at 22 pediatric otolaryngology sites), the mean number of procedures required per child is 4.4 per year and the average number of procedures required per child's lifetime is 19.7.¹⁴

Although the lesions of RRP are benign, the disease can be associated with serious complications, including potentially fatal acute airway obstruction and pulmonary dissemination with chronic obstructive pulmonary symptoms that can be fatal due to loss of functioning parenchyma. Malignant transformation is possible in chronic invasive papillomatosis and as a result of RRP irradiation or tobacco exposure.¹¹ The rate of malignant transformation is estimated at between 1% and 2%.¹⁵

Diagnosis and Management

The diagnosis of RRP is made by directly visualizing the larynx. Currently, there is no cure, and no therapeutic modality or combination of modalities has been shown to eradicate RRP.

Surgery remains the mainstay of RRP treatment. The goal of surgical procedures is removal of papillo-

mas and preservation of normal structure and function. In patients with anterior or posterior commissure lesions, it may be necessary to merely debulk the disease while preserving normal anatomy, in order to prevent the complications of anterior or posterior commissure web formation or stenosis and subsequent airway compromise. The CO₂ laser has been the basis for surgical treatment of RRP. Recent surgical alternatives include "microdebrider" or "shaver" instruments that may help reduce scarring.¹⁶ Some patients with chronic upper airway obstruction due to rapid growth or scarring may require tracheotomy. There have been recent reports of anecdotal success in slowing the rate of regrowth of RRP using the antiviral agent, cydofovir.^{17,18} The most commonly used adjuvant therapy against RRP is α -interferon.^{19,20} Although its mechanism of action is incompletely understood, it is thought to regulate the immune function and to inhibit viral protein synthesis. Early results from clinical trials using genetically engineered vaccines also offer some hope for vaccines as adjuvant therapies. The early studies of vaccines for HPV have focused on the HPV types with greater malignant potential.²¹

Voice Therapy and Supportive Services

Voice therapy should be included in the management of every child who is treated for RRP. Public law mandates that screening and referral services are provided for children with or at risk for developing communication disorders, including hearing loss and voice disorders. The administering agency typically is the Public Health Department or State Education Department. Further information and support are available through the American Speech-Language-Hearing Association (www.asha.org)—an excellent resource for both professionals and the public.

CONCLUSION

The diagnosis and management of hoarseness in a pediatric patient can be challenging and frustrating for all involved (child, parent, clinician), as care approaches that are successful in adults often are inappropriate or unfeasible in children. Not every child with a hoarse voice or cry will merit investigation beyond an assessment of the symptom. However, if hoarseness is associated with respiratory distress, tachypnea, tachycardia, cyanosis, dysphagia, chronic cough, failure to thrive, or recurrent or chronic pneumonia, the larynx must be visualized and a firm diagnosis of the etiology must be made. Any child with progressive hoarseness merits investigation, and the clinician should not wait until total aphonia or airway problems occur. In the absence

of acute respiratory symptoms or other indicators of significant underlying pathology, any child with hoarseness persisting beyond 2 weeks usually will benefit from a conservative course of voice therapy. **HP**

REFERENCES

1. Colletti RB, Christie DL, Orenstein SR. Statement of the North American Society for Pediatric Gastroenterology and Nutrition (NASPGN). Indications for pediatric esophageal pH monitoring. *J Pediatr Gastroenterol Nutr* 1995;21:253-62.
2. Stroh BC, Faust RA, Rimell FL. Results of esophageal biopsies performed during triple endoscopy in the pediatric patient. *Arch Otolaryngol Head Neck Surg* 1998;124:545-9.
3. Vandenplas Y. Reflux esophagitis in infants and children: a report from the Working Group on Gastro-Oesophageal Reflux Disease of the European Society of Paediatric Gastroenterology and Nutrition. *J Pediatr Gastroenterol Nutr* 1994;18:413-22.
4. Faust RA. Childhood voice disorders: ambulatory evaluation and operative diagnosis. *Clin Pediatr (Phila)* 2003;42:1-9.
5. Hirschberg J, Dejonckere PH, Hirano M, et al. Voice disorders in children. *Int J Pediatr Otorhinolaryngol* 1995;32 Suppl:S109-25.
6. Bauman NM, Sandler AD, Smith RJ. Respiratory manifestations of gastroesophageal reflux disease in pediatric patients. *Ann Otol Rhinol Laryngol* 1996;105:23-32.
7. Cohen SR, Thompson JW, Geller KA, Birns JW. Voice change in the pediatric patient. A differential diagnosis. *Ann Otol Rhinol Laryngol* 1983;92(5 Pt 1):437-43.
8. Mounts P, Shah KV, Kashima H. Viral etiology of juvenile- and adult-onset squamous papilloma of the larynx. *Proc Natl Acad Sci U S A* 1982;79:5425-9.
9. Terry RM, Lewis FA, Griffiths S, et al. Demonstration of human papillomavirus types 6 and 11 in juvenile laryngeal papillomatosis by in-situ DNA hybridization. *J Pathol* 1987;153:245-8.
10. Snowden RT, Thompson J, Horwitz E, Stocks RM. The predictive value of serum interleukins in recurrent respiratory papillomatosis: a preliminary study. *Laryngoscope* 2001;111:404-8.
11. Derkay CS. Task force on recurrent respiratory papillomas. A preliminary report. *Arch Otolaryngol Head Neck Surg* 1995;121:1386-91.
12. Morgan AH, Zitsch RP. Recurrent respiratory papillomatosis in children: a retrospective study of management and complications. *Ear Nose Throat J* 1986;65:19-28.
13. Kashima HK, Shah F, Lyles A, et al. A comparison of risk factors in juvenile-onset and adult-onset recurrent respiratory papillomatosis. *Laryngoscope* 1992;102:9-13.
14. Armstrong LR, Derkay CS, Reeves WC. Initial results from the national registry for juvenile-onset recurrent respiratory papillomatosis. RRP Task Force. *Arch Otolaryngol Head Neck Surg* 1999;125:743-8.
15. Dedo HH, Yu KC. CO(2) laser treatment in 244 patients with respiratory papillomas. *Laryngoscope* 2001;111:1639-44.
16. El-Bitar MA, Zalzal GH. Powered instrumentation in the treatment of recurrent respiratory papillomatosis: an alternative to the carbon dioxide laser. *Arch Otolaryngol Head Neck Surg* 2002;128:425-8.
17. Snoeck R, Wellens W, Desloovere C, et al. Treatment of severe laryngeal papillomatosis with intralesional injections of cidofovir [(S)-1-(3-hydroxy-2-phosphonylmethoxypropyl)cytosine]. *J Med Virol* 1998;54:219-25.
18. Pransky SM, Magit AE, Kearns DB, et al. Intralesional cidofovir for recurrent respiratory papillomatosis in children. *Arch Otolaryngol Head Neck Surg* 1999;125:1143-8.
19. Healy GB, Gelber RD, Trowbridge AL, et al. Treatment of recurrent respiratory papillomatosis with human leukocyte interferon. Results of a multicenter randomized clinical trial. *N Engl J Med* 1988;319:401-7.
20. Leventhal BG, Kashima HK, Weck PW, et al. Randomized surgical adjuvant trial of interferon alpha-n1 in recurrent papillomatosis. *Arch Otolaryngol Head Neck Surg* 1988;114:1163-9.
21. Adams M, Borysiewicz L, Fiander A, et al. Clinical studies of human papilloma vaccines in pre-invasive and invasive cancer. *Vaccine* 2001;19:2549-56.

Copyright 2003 by Turner White Communications Inc., Wayne, PA. All rights reserved.